



Equine Clinic
bvpec@bvp.com.au
03 5334 6756
54 Midas Rd
Miners Rest 3350

31-12-2024

Mr Dom Sutton
48 Loch Avenue
Ballarat Central, Victoria 3350

Dear Dom,

Re: King Neptune

Under general anaesthesia a bilateral ventriculectomy and cordectomy was performed. The ventricles were excised and then the opening sutured closed on both sides. This technique prevents vocal cord collapse which is one part of the respiratory obstruction in this horse. He also has some chondritis of the left arytenoid, recurrent laryngeal neuropathy (roaring) and ventral luxation of the apex of the corniculate cartilages (VLAC). Because of the complexity of the issues and the likelihood that a simple tieback would not fix all of the problems and carries a number of complications this first step has been performed. Healing time is 4-6 weeks and hopefully the increase in airway diameter helps him get enough air to be competitive. If this is not sufficient then we either re-visit other procedures or consider retirement.

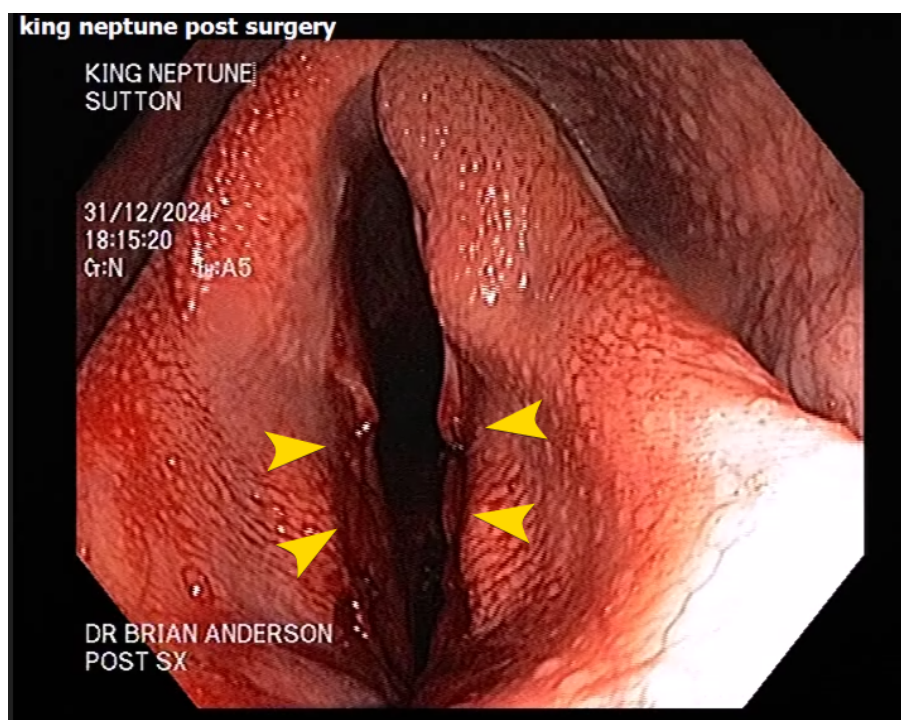
King Neptune recovered well from the procedure and can be discharged tomorrow after 10 am so long as all clinical signs are normal.

Complications are not common but can include infection, suture breakdown, antibiotic associated colitis and coughing.

Please do not hesitate to call me if you have any questions

Yours sincerely

Dr Brian Anderson, BVSc (Massey), MVSc, MS, MACVSc, Diplomate ACVS Registered Specialist in Equine Surgery
VPRBV: 2261 AVA: 5729
Ballarat Veterinary Practice
Cc Mr Nathan Bennett, Dr Matt Morahan and Dr Joel Hummel



Post op picture of the ventriculocordectomy showing the openings of the ventricles have been sutured (yellow arrows)