



**SYDNEY  
EQUINE**

Monday, 7 July 2025

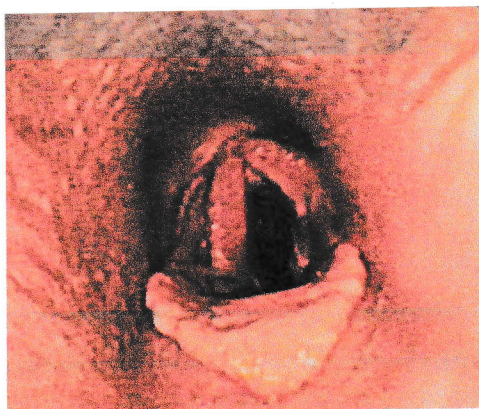
### **Veterinary Report**

**HORSE  
MICROCHIP**

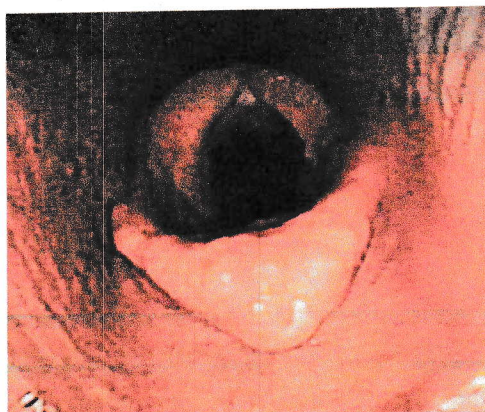One Last Shot – 4yo Bay Gelding  
985100012180725

On the 7<sup>th</sup> July 2025, One Last Shot underwent upper airway endoscopic examination prior to being entered into the Inglis Digital Online Sales catalogue. One Last Shot reportedly underwent a surgical tie-back procedure (laryngoplasty) on 16/04/2024.

On endoscopic examination it was apparent that the gelding had undergone a left sided laryngoplasty. The left arytenoid was not mobile and had a high degree of abduction (Dixon scale - Grade 2).



*Larynx at rest*



*Larynx at full abduction*

If you have any further questions regarding this report, please do not hesitate to contact the office on +61 437 420 581.

**Dr. Richard Birnie**

**Equine Veterinarian | VPB N° V12296**

BVMBVS (Hons), MRes

PLEASE ENSURE THAT THIS REPORT IS FORWARDED TO THE HORSES OWNER AND/OR THE PERSON RESPONSIBLE FOR THE CARE OF THE HORSE, AS WELL AS THE INSURER IF APPLICABLE.

+61 0437 420 581  
office@sydneyequine.com.au  
sydneyequine.com.au

Sydney Equine Practice Pty Ltd  
ABN 86 153 992 940  
PO Box 521, Kensington NSW 2033