

Veterinary Surgeons

Leanne Begg BVSc Dip VCS MS MANZCVS Dip ACVIM
Jonathan Lumsden BVSc Dip VCS MS Dip ACVS
James Whitfield BVSc
Richard Humberstone BVSc Cert EP MRCVS
Chris O'Sullivan BVSc MS Dip VCS MANZCVS Dip ACVS
Hayley Lang DVM ACVS
Rachel Lambeth BVSc Dip VCS MVCS
Ramon Perez DVM
Darren Feary BVSc MS Dip ACVIM Dip ACVECC
Megan Bartels DVM
Emily Sanford DVM
Matthew Oliver Heaton BVet Med MRCVS
Jessica Flook DVM
Anna Robson BVMS MRCVS
Tate Morris DVM DACVS (LA)
Gideon Stemmet BSc BVSc MSc MANZCVS



Est 1951 by Percy Sykes AM
Veterinarians • Equine Medicine & Surgery

Veterinary Surgeons

Raphael Labens Mag. Med. Vet. CertES(Orth) MVM PhD
DiplECVS DiplACVS DipACVSMR
Emma Cox BVSc MVCS MVS MANZCVS
Annabelle Trainor BSc (Hons) DVM MANZCVS
Pauline Kos DVM
Chloe Combe BVSc BSc
Claudia Rigney DVM BVBS
Robin Tai BVSc BSc
Naomi Duncan BVMS
Evelyn Hodgson BVSc MSc
Issy Dyer DVM BSc (Hons)
Clodhna Symington BVMS BSc
Resident Consultants
Karon Hoffmann BVSc Dip VCS MVSc PhD Dip ECVDI
Colin Dunlop BVSc Dip ACVA
Treve Williams OAM BVSc MRCVS
Frederik Pauwels DVM, CertVA, DipACVS, DipECVDI

15th December 2023

VETERINARY REPORT FOR 'GRACED'

Signalment:

Owner:

Spelling:

Referring Veterinarian:

3-Year-Old Chestnut Thoroughbred Filly - 985100012180165

Dynamic Syndications – Adam Watt

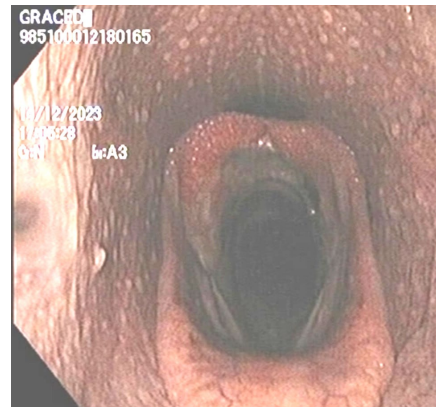
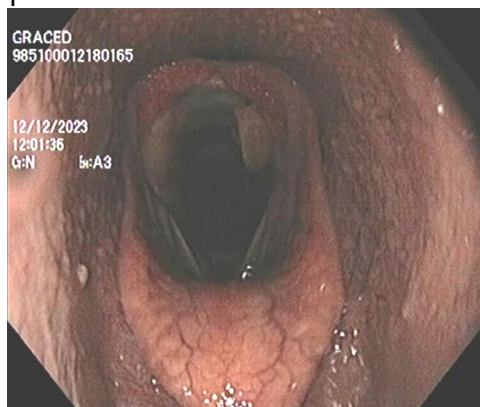
Bimbadeen Park

Dr David Garth BVSc - *Thank you for referring this case*

On the 12th of December 2023, 'Graced' was referred to **REC Equine Specialist Centre**, for surgical treatment of chronic left laryngeal cartilage localised infection (arytenoid granuloma). Standing video endoscopic examination of the larynx revealed a large granuloma on the left arytenoid (corniculate) with mild thickening of the left corniculate and a mild reduction of opening function (abduction) of the left side of the larynx evident, being only able to achieve ~90% of full abduction of the left cartilage. Ultrasound examination of the larynx revealed normal laryngeal muscle (CAL) appearance and a mild increase in thickness of the body of the cartilage.

On the 13th of December 2023, 'Graced' was anaesthetised and a laryngotomy was performed for the resection of the granuloma from the left arytenoid. The surgical incision was left open to heal by second intention. The infected tissue was sampled and submitted for culture and sensitivity (*results pending*). The surgical procedure was performed without complication and a good result was achieved. She recovered uneventfully from general anaesthesia.

Video-endoscopic examination of the surgery site the following day revealed a good surgical outcome. Since surgery 'Graced' has done very well, she has been stall rested with hand walking, treated with antibiotics and anti-inflammatories, and has continued to breathe comfortably, eat and drink without problem.



Pre (left) and post (right) endoscopic images.

PLEASE ENSURE THAT THIS REPORT IS FORWARDED TO THE HORSE'S OWNER AND THE PERSON RESPONSIBLE FOR THE FUTURE CARE OF THE HORSE, AS WELL AS TO THE INSURER, IF APPLICABLE

373-379 Wallgrove Road | Horsley Park | NSW 2175 | Sydney, Australia
PO Box 355 Horsley Park NSW 2175 Sydney Australia
P (612) 9399 7722 | F (612) 9398 5649
E reception@recequine.com.au
ABN: 17352081430


-2-
'Graced'

Aftercare recommendations for 'Graced' include:

- Stall rest and hand walking only for the next three (3) weeks. The top door of the stable should be kept closed to prevent rubbing of surgical wounds.
- The wound under the throat should be cleaned twice daily with the solution provided and Vaseline® smeared around it. This wound will take about three weeks to heal.
- Penicillin 44ml twice daily in muscle and 40ml of gentamycin IVC once daily for 5 days. Ongoing oral antibiotic therapy will depend on the culture results which should be known on Monday.
- Give 10 ml Bute paste once daily by mouth for a further 5 days.
- Temperature should be taken twice daily for the next seven days. If there is any increase in temperature (above 38.5°C), dullness of demeanour, loss of appetite or increased lameness, swelling or wound discharge, please call.
- Feed should be dampened, otherwise feed as normal.
- Repeat scope in 3 weeks prior to allowing small paddock for ~1 month.
- Repeat endoscopy should be performed in 6-8 weeks to determine if healing is adequate to return to training. In a small number of horses, areas of the surgery site may again develop granulation tissue that may require further antibiotic therapy or occasionally surgery correction prior to commencing training. Rarely the infection progresses to involve the body of the cartilage requiring surgical removal of the cartilage.

The prognosis for returning to racing is good.

Please call should you have any questions regarding this report.



.....NSW V3860
Dr Jonathan Lumsden BVSc Dip VCS MS Dip ACVS
Specialist Equine Surgeon
REC Equine Specialists