



130 Tarata Road
Guanaba QLD 4210
Ph: 0417292705
tim@trhequinevets.com.au

TRH Equine Veterinary Services Pty Ltd.
ABN - 49 614 262 681

Dr Timothy R Hawthorne BVSc (Hons) BSc (Hons) CertAVP MRCVS
Dr Naomi Gaskell BVM&s MRCVS

Certificate of Veterinary Examination

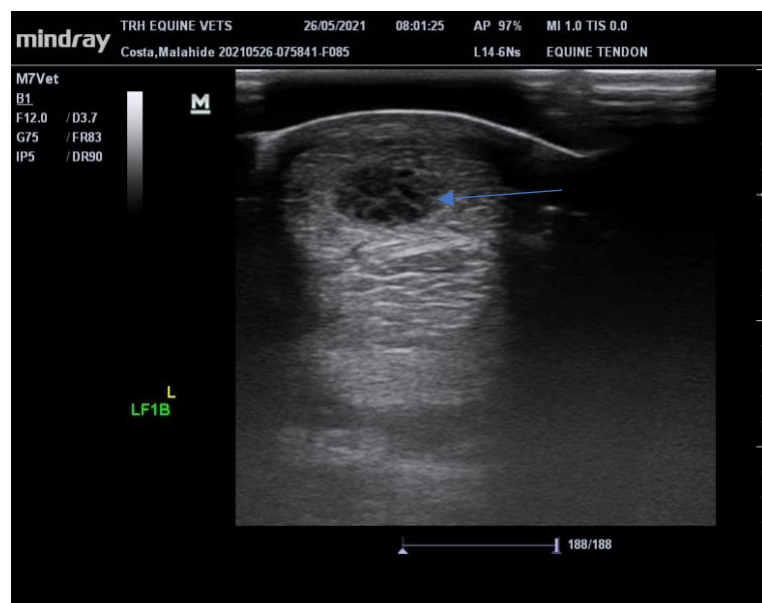
Date: 26th May 2021
Horse: Malahide
DOB: 24/09/15
Microchip: 985100012059078
Trainer: Michael Costa

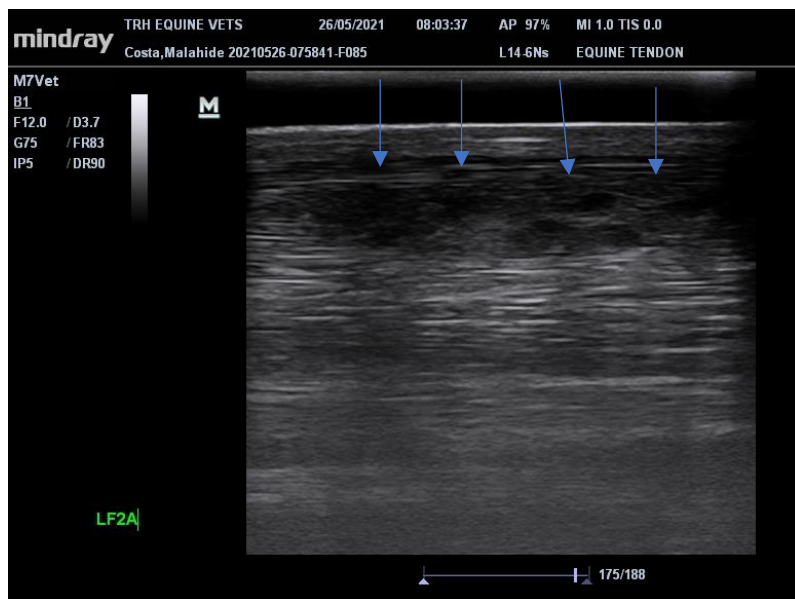
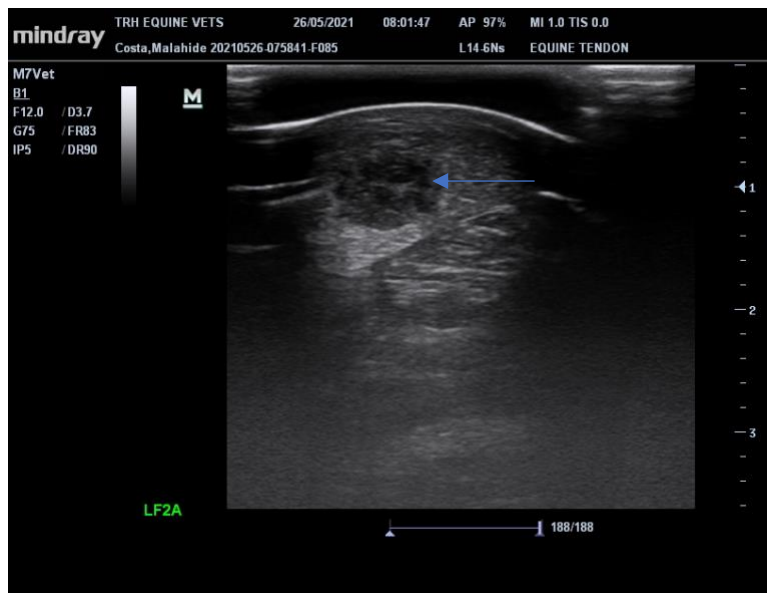
The above-named horse was examined on the 26th of May 2021 following reports of a swelling to the left fore that morning. On examination the mare presented with an enlargement to the flexor tendons at the back of the cannon on the left fore. On palpation there was a moderate pain response and thickening to the Superficial digital flexor tendon when palpated. No lameness was evident.

Ultrasound examination was performed of the area of concern revealing a Core lesion with significant fiber damage (Black area within the tendon) extending from 1a (Proximal cannon) to 3a (Distal Cannon). Some cross-sectional areas are significant in size with the lesion occupying approximately 60% of the tendon.

This type of injury would require a long period of convalescence in the paddock with a likely recovery time of 9-12 months or alternatively retirement from racing. Some therapies that may help healing are intralesional injections such as PRP (Platelet Rich Plasma) which can be discussed if owners decide not to retire the mare. Prognosis for return to racing would be guarded.

Images below highlighted with blue arrows show the area of injury.





If you have any further questions please do not hesitate to contact me.
Kind Regards

Dr Naomi Gaskell BVM&s MRCVS
(Veterinary Surgeon)