

VETERINARY REPORT

Horse:	Al Jood	Date:	23 rd December 2020
Signalment:	5YO Bay TB Mare	Microchip:	985100012124529
Trainer:	Chris Munce		

Al Jood was recently examined for swelling of the left fore palmar cannon region which became apparent following routine trackwork that morning. There was a mild amount of heat and pain on palpation of the area, however there was no lameness at the hand led trot. A small abrasion was apparent on the lateral aspect of the cannon so the mare was treated with anti-inflammatory and anti-biotic treatment for several days. The swelling of the area did not resolve with treatment so an ultrasound examination was performed on Monday 21st December.

Ultrasound of the area revealed a large core lesion extending almost the entire length of the body of the suspensory ligament (see images below).

The location and extent of this injury would require a long rehabilitation period (9-12mths) and carries a poor to guarded prognosis for return to racing, due to the risk of re-injury. Given these considerations, it was recommended that the mare retire from racing.

After a period of rest, the mare may be suitable for a lower intensity alternative discipline and she is suitable for a broodmare option.



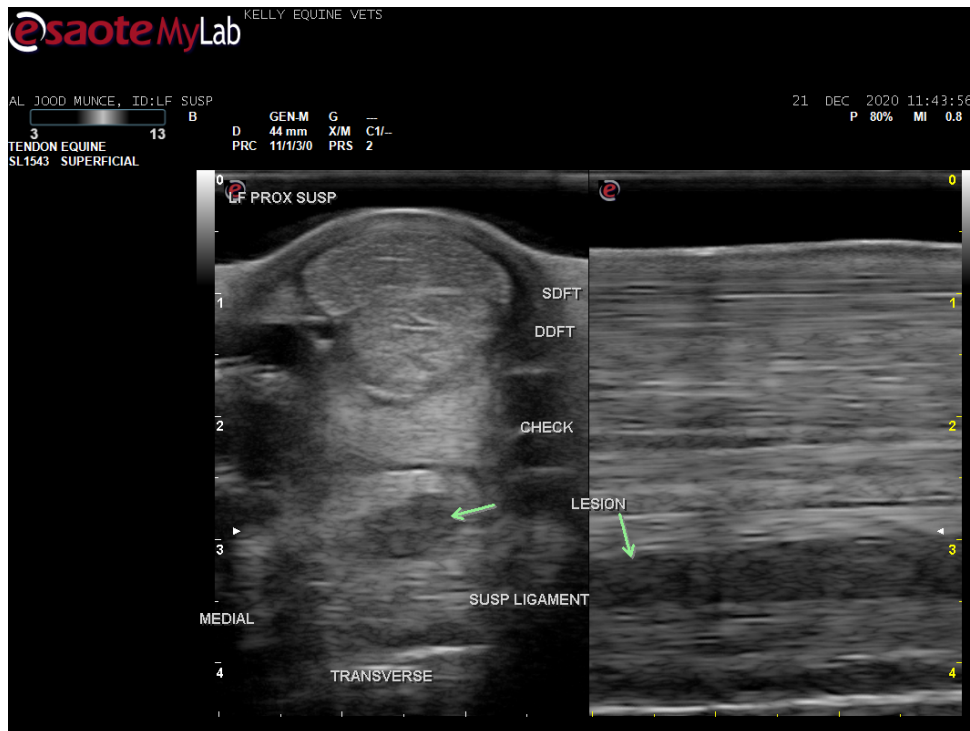


Fig 1 – The black area with arrow indicates the torn suspensory ligament fibres. Image is shown in cross section and longitudinal section.

Please contact me if you have any questions regarding this report.

Kind Regards

Dr Leticia Kelly BVSc MACVSc