



Tweedie & Associates Equine Veterinary Services
PO BOX 525
Somerville, VICTORIA 3912, Australia
Phone: 0434318471
Fax: 0359780457
Email: info@tevs.com.au

X-ray Report

07, October, 2019

Patient ID: Untouched

DOB:

Study Description: Knees

Referring Physician: M. A. Tweedie

Patient Name: Morningrise Stud

Sex: F

Study Date: 07, October, 2019

Clinical Examination :

Mild to moderate effusion of both middle carpal joints. Left greater than right

X-ray Findings :

- Left Carpus:
 - Spurring distal radial carpal bone in the middle carpal joint
 - Lytic lucencies along the radial facet of the third carpal bone.
 - Remodelling of the proximal intermediate carpal bone in the radial- carpal joint.
- Right Carpus:
 - Spurring distal radial carpal bone in the middle carpal joint
 - Lytic lucencies along the radial facet of the third carpal bone.

Recommendations :

The spurring on the radial carpal bone appears to be old and is not active on these radiographs. The changes on the third carpal bone are of a more active nature.

I would expect that this horse will need some veterinary attention in this region as she progresses through training. Training on an incline and using alternative training methods will be to an advantage for the long-term soundness of this horse.



Michael A. Tweedie

M.A, VetMB, MRCVS

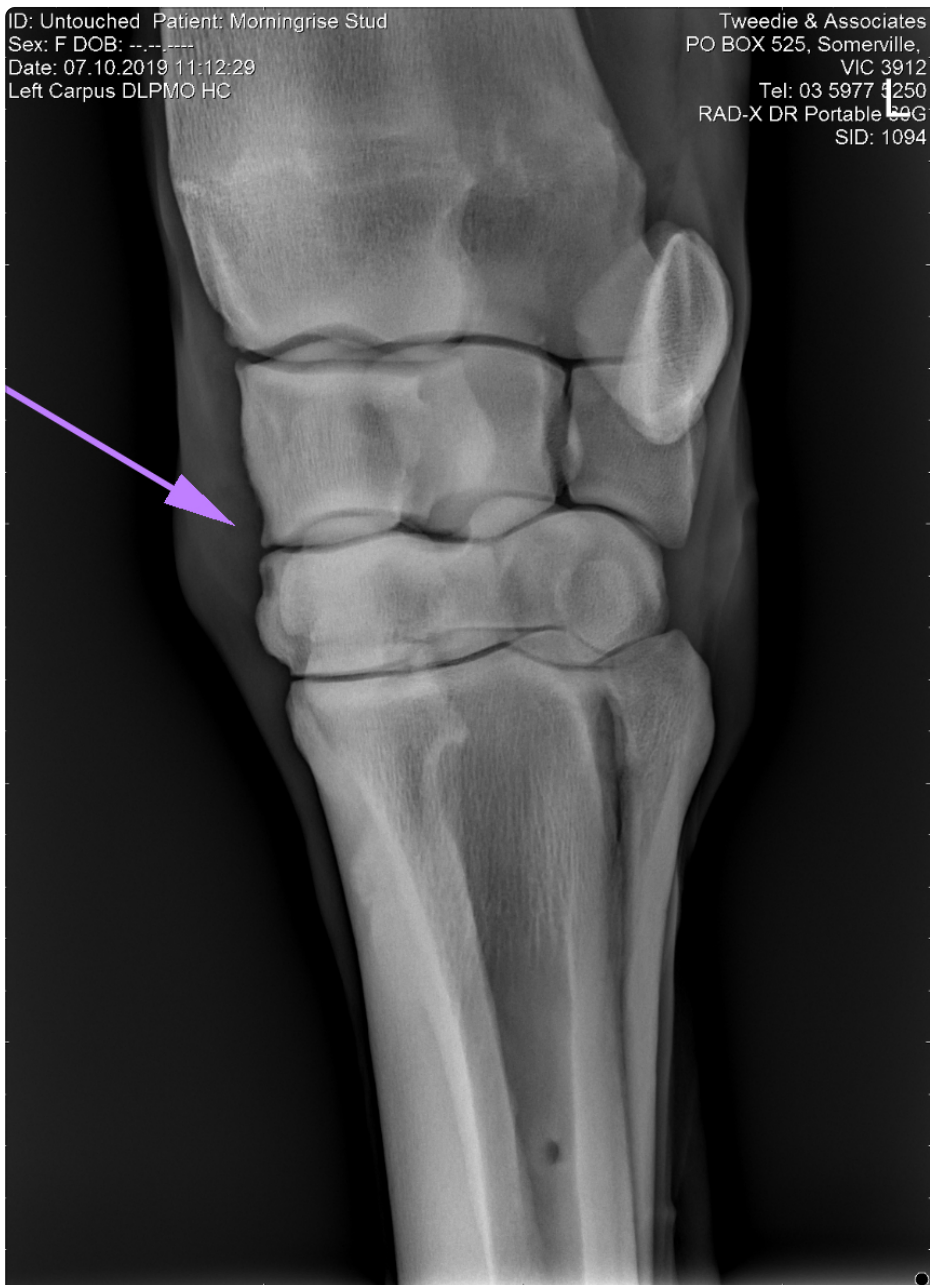
Vic Vet: 4225

Tel: 0434318471

Tweedie & Associates Equine Veterinary Services

PO BOX 525 - Somerville, VICTORIA 3912, Australia

Phone: 0434318471 - Fax: 0359780457 - Email: info@tevs.com.au

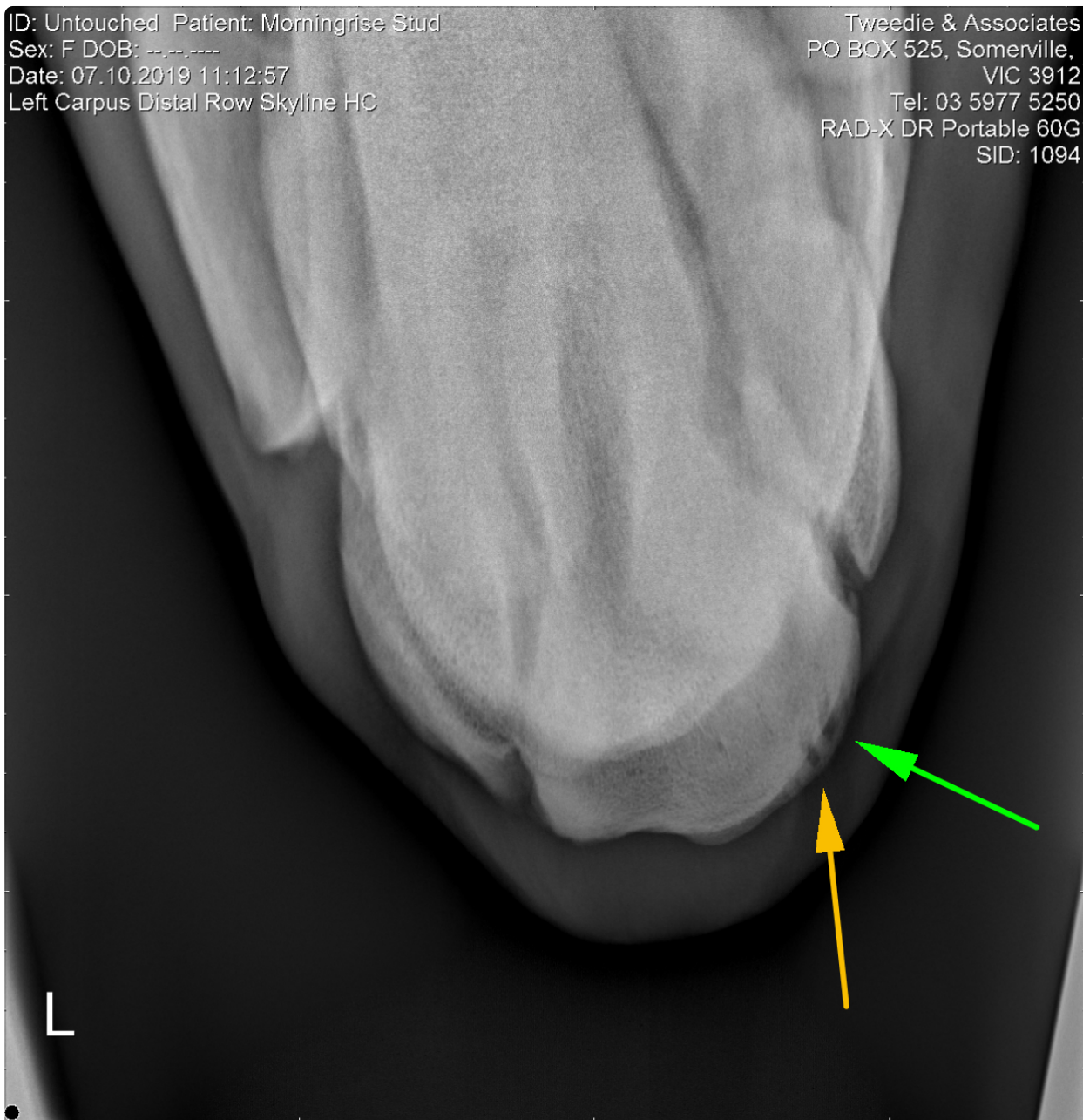


Left fore Carpus

The arrow shows the spur on the distal radial carpal bone

ID: Untouched Patient: Morningrise Stud
Sex: F DOB: ----
Date: 07.10.2019 11:12:57
Left Carpus Distal Row Skyline HC

Tweedie & Associates
PO BOX 525, Somerville,
VIC 3912
Tel: 03 5977 5250
RAD-X DR Portable 60G
SID: 1094

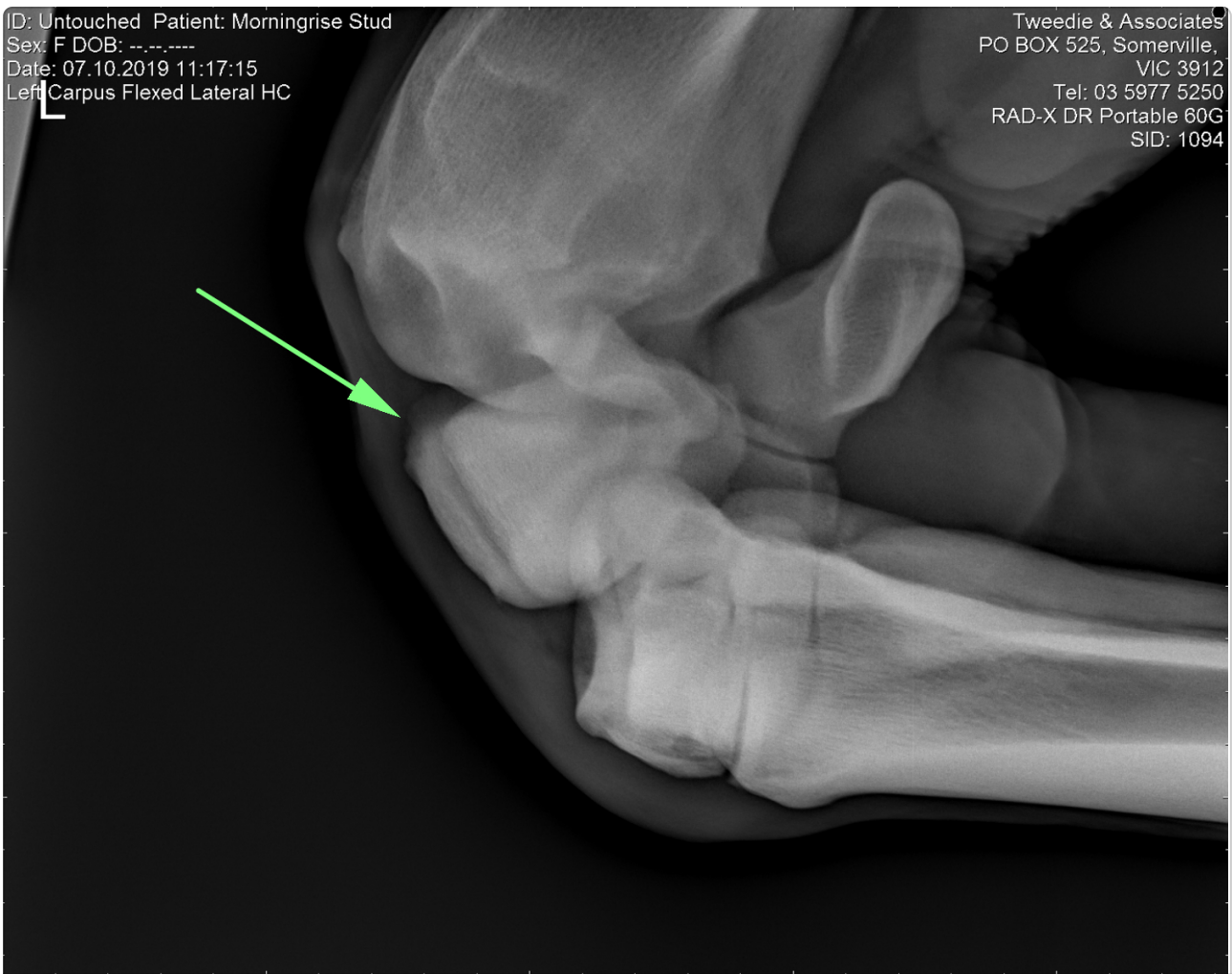


Left fore carpus

The arrows show the lytic edge to the third carpal bone.

ID: Untouched Patient: Morningrise Stud
Sex: F DOB: ---,---
Date: 07.10.2019 11:17:15
Left Carpus Flexed Lateral HC

Tweedie & Associates
PO BOX 525, Somerville,
VIC 3912
Tel: 03 5977 5250
RAD-X DR Portable 60G
SID: 1094

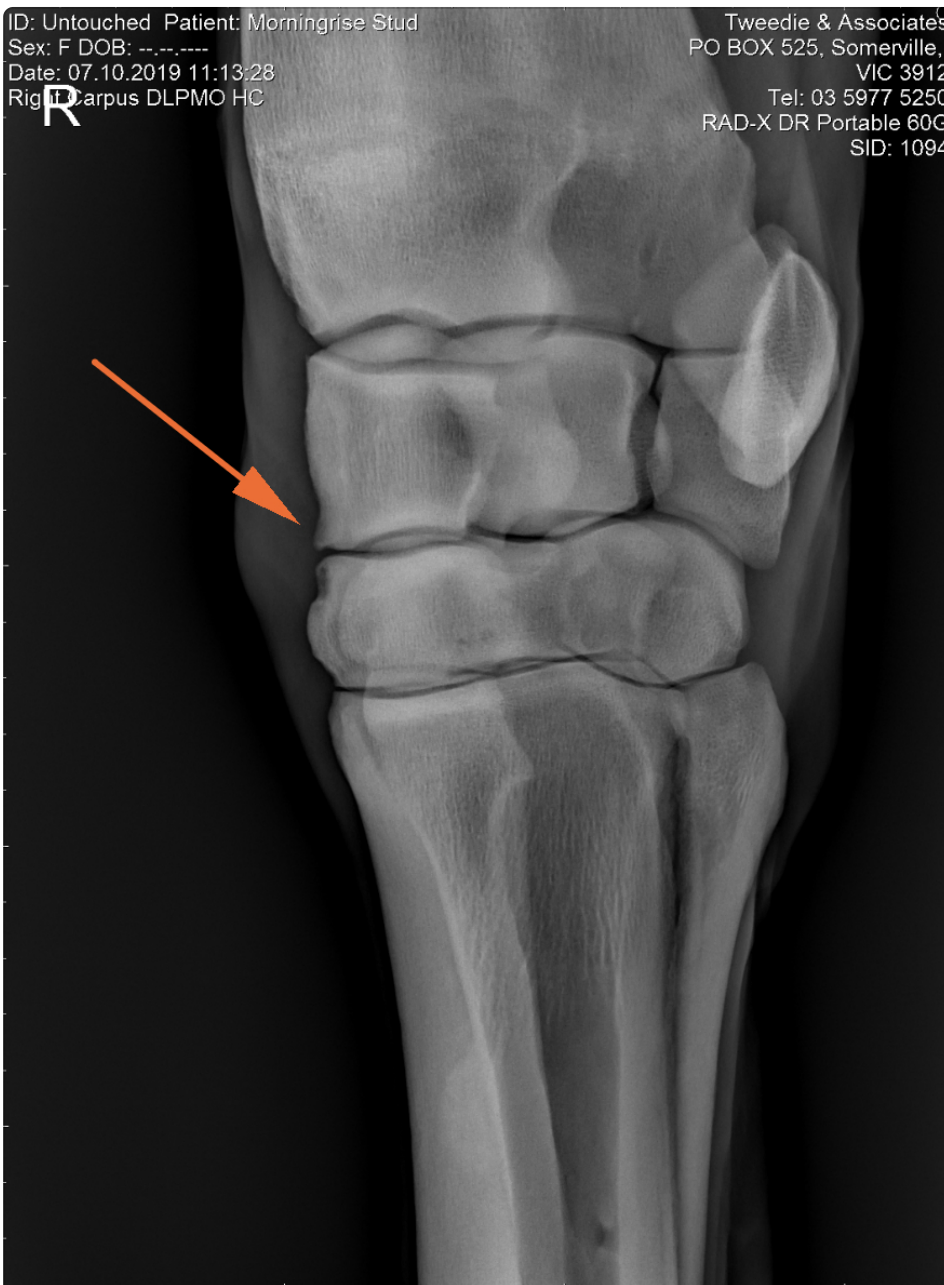


Left fore carpus

The arrow shows the remodelling along the edge of the proximal intermediate carpal bone.

ID: Untouched Patient: Morningrise Stud
Sex: F DOB: ---,---,----
Date: 07.10.2019 11:13:28
Right Carpus DLPMO HC

Tweedie & Associates
PO BOX 525, Somerville,
VIC 3912
Tel: 03 5977 5250
RAD-X DR Portable 60G
SID: 1094

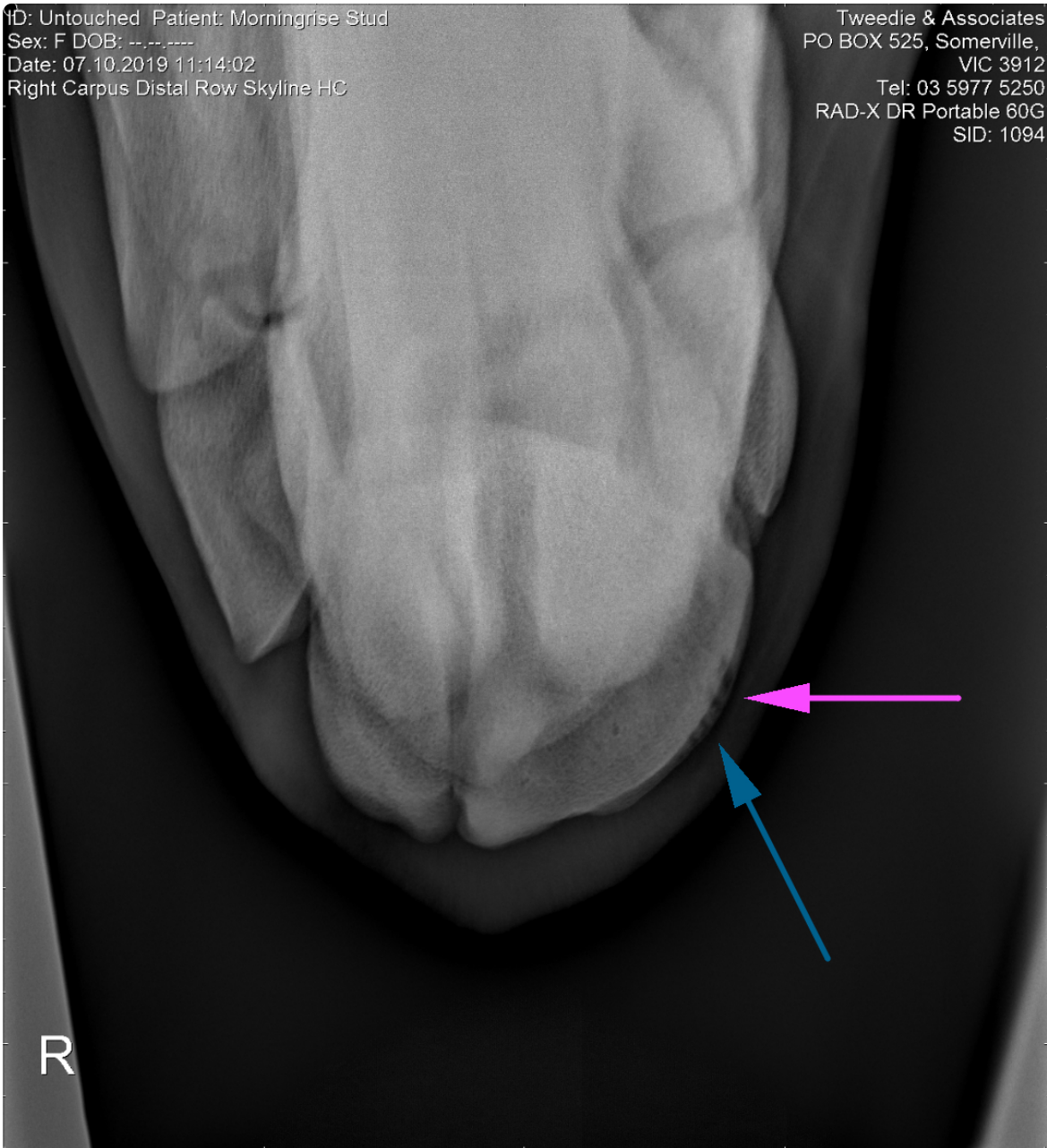


Right fore Carpus

The arrows show the spur on the distal radial carpal bone

ID: Untouched Patient: Morningrise Stud
Sex: F DOB: --.--.----
Date: 07.10.2019 11:14:02
Right Carpus Distal Row Skyline HC

Tweedie & Associates
PO BOX 525, Somerville,
VIC 3912
Tel: 03 5977 5250
RAD-X DR Portable 60G
SID: 1094



Right fore carpus

The arrows show the lytic edge to the third carpal bone.