



ABN 40 119 407 715

Sturt Street:

1410 Sturt St., Lake Wendouree 3350
Ph. (03) 5331 1533 Fax (03) 5331 3337
bvp@bvp.com.au

Howitt Street:

1329 Howitt St., Wendouree 3355
Ph. 5339 2266 Fax 5338 1588
wvc@bvp.com.au

Equine Clinic:

54 Midas Road, Miners Rest 3352
Ph. 5334 6756 Fax 5334 6800
bvpec@bvp.com.au

www.bvp.com.au www.facebook.com/ballaravet www.facebook.com/ballaratequineclinic Instagram: @ballaratvetpractice

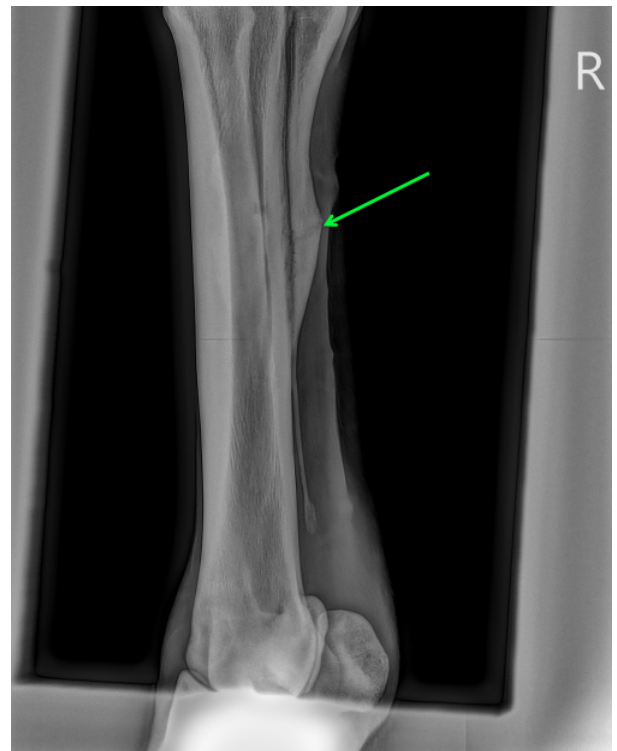
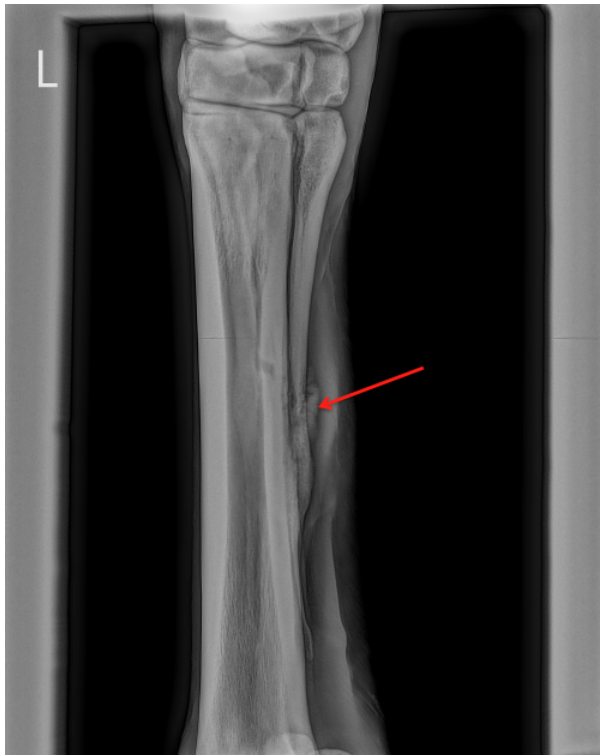
19-07-2019

Mr Mitch Freedman
Mitchell Freedman Racing
PO Box 54
Miners Rest, Victoria 3352

Dear Mitch,

Re: Tottie (Pearl De Vere)

Tottie was examined by the Ballarat Veterinary Practice Equine Clinic, at your stables, on 18th July 2019. She had a painful periosteal lump on her left front medial splint bone. There was also evidence of previous periosteal reactions on the left front lateral splint and both splint bones on the right front leg. Digital radiographs found an acute reactive "splint" on the LF medial splint bone (red arrow). The right front lateral splint was inactive however there was evidence of an old fracture line (green arrow).



Diagnosis:

Tottie has a reactive medial splint on the left front leg.

Treatment:

There have been all sorts of topical treatments used for these with varying success. Inevitably these horses need a short spell to let the reactive bone settle down. Ice boots, anti-inflammatory medications and topical medications such as DMSO

Partners

Dr. I. C. FULTON BVSc (Hons), MS (Michigan),
FANZCVS,
Registered Specialist in Equine Surgery

Dr. B. H. ANDERSON BVSc (Massey), MVSc, MS,
MANZCVS, Diplomate ACVS,
Registered Specialist in Equine Surgery

Dr. A. W. LUTTRELL BVSc
Dr. S. A. GREEDY BVSc, MANZCVS
Dr. A. R. CUST BSc, BVSc (Hons), MVSc



ABN 40 119 407 715

Sturt Street:

1410 Sturt St., Lake Wendouree 3350
Ph. (03) 5331 1533 Fax (03) 5331 3337
bvp@bvp.com.au

Howitt Street:

1329 Howitt St., Wendouree 3355
Ph. 5339 2266 Fax 5338 1588
wvc@bvp.com.au

Equine Clinic:

54 Midas Road, Miners Rest 3352
Ph. 5334 6756 Fax 5334 6800
bvpec@bvp.com.au

www.bvp.com.au www.facebook.com/ballaravet www.facebook.com/ballaratequineclinic Instagram: @ballaratvetpractice

roll-on help with this process. Tottie has splints on all four front splint bones indicating a chronic ongoing issue. I think it is likely that further "splints" will develop in the future and although these can often be managed, her racing preparations may be frustrating.

If you have any questions please contact me at the clinic on 5334 6756.

Sincerely,

Dr Andrew Cust BSc, BVSc, MVSc.
Ballarat Veterinary Practice Equine Clinic
VPBV: 4101 AVA: 9861

Partners

Dr. I. C. FULTON BVSc (Hons), MS (Michigan),
FANZCVS,
Registered Specialist in Equine Surgery

Dr. B. H. ANDERSON BVSc (Massey), MVSc, MS,
MANZCVS, Diplomate ACVS,
Registered Specialist in Equine Surgery

Dr. A. W. LUTTRELL BVSc
Dr. S. A. GREEDY BVSc, MANZCVS
Dr. A. R. CUST BSc, BVSc (Hons), MVSc