

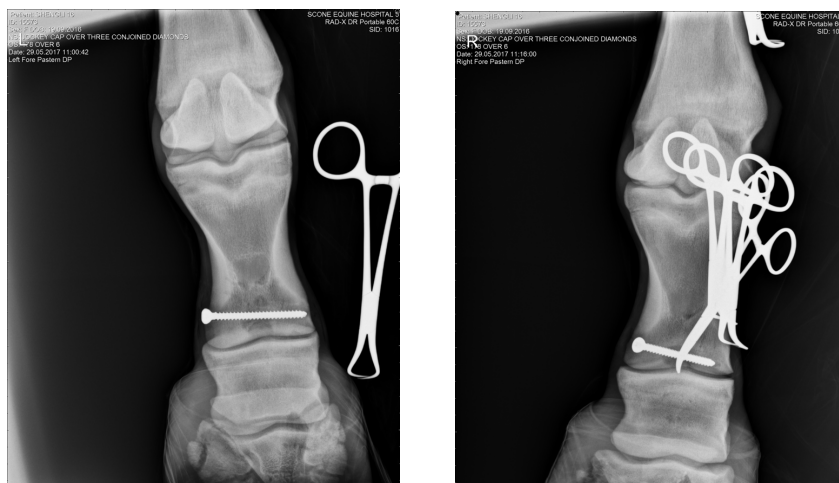
Monday, 29 May 2017

VETERINARY REPORT: Shengli '16

Report requested by: Arrowfield Pastoral Pty Ltd / Arrowfield / Insurance Co.

On Monday 29th May, the above mentioned weanling presented to Scone Equine Hospital for surgery of subchondral bone cysts of both front pasterns. Prior to surgery, the weanling was sedated and x-rays were taken of all 4 pasterns. X-rays showed subchondral bone cysts present in the distal aspect of all 4 pasterns, however only the front lesions were large enough to warrant placement of a transcondylar screw.

Under radiographic guidance, transcondylar screws were placed through the left and right fore pastern subchondral cysts (shown below). The transcondylar screw placed in the right pastern is shorter than that placed in the left. This screw was placed more distally to compress the cyst, and it was important that it didn't engage the trans-cortex due to the close proximity with the pastern joint.



The image on the left shows screw placement in the left pastern cyst, and the image on the right shows screw placement in the right pastern cyst.



**Scone
Equine Hospital**

Dedicated expert care

The weanling recovered uneventfully and was transferred to our Intensive Care Unit for overnight monitoring.

On discharge please follow the instructions detailed below:

1. Please confine to a box for 3 weeks, and then a small yard for a further 3 weeks. Following this she can be moved to a normal spelling paddock.
2. Bandage change every day until 05/06/17 and then every other day until 2 days post suture removal.
3. Please monitor for any signs of discharge, swelling or the development of lameness
4. Suture removal on 12/06/2017.
5. Repeat radiographs in approximately 3 months time and then every month thereafter. The timing of cyst resolution will determine the date of screw removal.

The prognosis for future racing is good, but this is largely determined by the response to screw placement.

If you have any questions regarding this case please contact me at Scone Equine Hospital on the number below.

Dr Angus R Adkins BVSc FACVSc

Fellow and Specialist in Equine Surgery

Nominated Veterinarian Hong Kong Jockey Club

VPB Registration: 6162

Please ensure that this report is forwarded to the horse's owner and the person responsible for the future care of the horse, as well as to the insurer, if applicable.

SCONE EQUINE GROUP
Veterinary Excellence

Scone Equine Hospital | 106 Liverpool Street Scone NSW 2337 | PO Box 280 Scone NSW 2337

T +61 2 6545 1333 | F +61 2 6545 2903 | info@sconeequine.com.au

SEH Intensive Care Unit | Clovelly | St Aubins Street Scone NSW 2337 | PO Box 280 Scone NSW 2337

T +61 2 6545 1433 | F +61 2 6545 1436 | icu@sconeequine.com.au

SEH Denman | 26 Ogilvie Street Denman NSW 2328 | PO Box 41 Denman NSW 2328

T +61 2 6547 2222 | F +61 2 6547 2887 | denman@sconeequine.com.au

www.sconeequinehospital.com.au | ABN 69 138 546 595