

Veterinary Surgeons

Greg Nash BVSc MANZCVS
Leanne Begg BVSc Dip VCS MS MANZCVS Dip ACVIM
Jonathan Lumsden BVSc Dip VCS MS Dip ACVS
James Whitfeld BVSc
Richard Humberstone BVSc Cert EP MRCVS
Chris O'Sullivan BVSc MS Dip VCS MANZCVS Dip ACVS
Hayley Lang DVM ACVS
Rachel Lambeth BVSc Dip VCS MVCS
Ruth Franklin BVetMed MRCVS
Rachel Salz BSc (Hons) BVetMed MRCVS Dip ACVSMR
Victoria Locke MA VetMB CertAVP(EM) MRCVS
Ilona Bayliss MA VetMB MRCVS
Ramon Perez DVM



Est 1951 by Dr Percy Sykes AM
RANDWICK EQUINE CENTRE

Veterinarians • Equine Medicine & Surgery

Veterinary Surgeons

Thomas Bayes BVM BVS (Hons) MRCVS
Sarah Smith BVM&S MRCVS
Kate Robson BVetBiol BVSc (Hons)
Megan Bartels BVS (Hons)
Lucy McGlashan-Morris BVet Med MRCVS
Mark O'Sullivan MVB

Resident Consultants

Karon Hoffmann BVSc Dip VCS MVSc PhD DipECVDI
D R Hutchins BVSc Hon.DVSc FANZCVS OAM
Trevé Williams BVSc MRCVS
Colin Dunlop BVSc Dip ACVA

4th January 2018

VETERINARY REPORT FOR 'ROCK PRODIGY'

Signalment:

5-Year-Old Bay Thoroughbred Gelding -985125000063814

Trainer:

A & E Cummings

Spelling@:

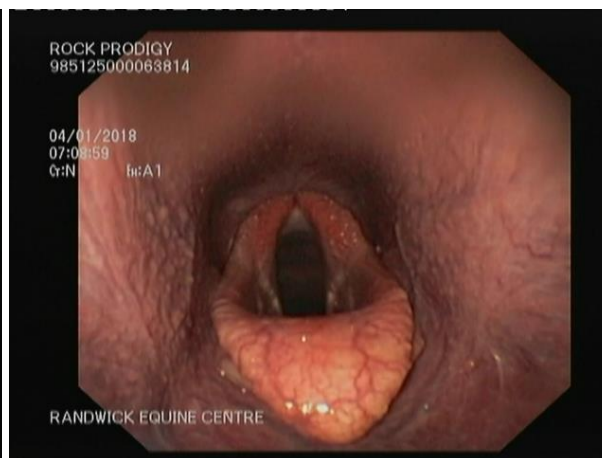
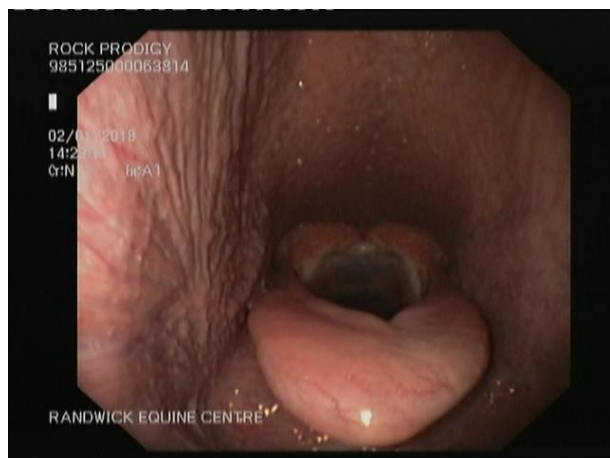
Princes Farm

Veterinarian:

Dr Gary Baitz BVSc – Thank you for referring this case

On the 2nd of January 2018, 'Rock Prodigy' was referred to Randwick Equine Centre for assessment and surgical correction of a throat abnormality recognised as an 'epiglottic entrapment'. Epiglottic entrapment represents a fold of membrane that becomes entrapped over the front of the larynx which reduces the airway size and causes abnormal airflow when exercising affecting performance. Pre-operative video-endoscopic examination revealed an uncomplicated entrapped fold likely to cause significant airway obstruction.

On the 3rd of January 2018, 'Rock Prodigy' was anaesthetised and the intermittent entrapping fold was surgically released (axial division with hooked bistoury) by dividing the fold under video-endoscopic guidance. A good result from the surgery was achieved and he recovered well from general anaesthesia. Video-endoscopic examination the following day showed the epiglottis to be un-entrapped and of normal appearance. He has been treated post-surgery with procaine penicillin, gentamycin, throat spray, phenylbutazone and dexamethasone.



Pre-operative image (left) and post-operative image (right) showing the epiglottis un-entrapped.

.../2

PLEASE ENSURE THAT THIS REPORT IS FORWARDED TO THE HORSE'S OWNER AND THE PERSON RESPONSIBLE FOR THE FUTURE CARE OF THE HORSE, AS WELL AS TO THE INSURER, IF APPLICABLE

3 Jane Street Randwick NSW 2031 Sydney Australia Postal PO Box 195 Randwick NSW 2031 Sydney Australia

Phone (612) 9399 7722 Fax (612) 9398 5649 E-Mail Address reception@randwickequine.com.au

-2-
'Rock Prodigy'

Aftercare recommendations for 'Rock Prodigy' include:

- Stall rest and hand walking for two (2) weeks. After this time he may be turned out in a small yard for a further two (2) weeks.
- 2g (10mls) oral phenylbutazone once daily for five (5) days.
- Give Bromotrimidine antibiotic (2.5 scoops in feed twice daily) for seven (7) days.
- Anti-inflammatory throat spray – give 10ml morning and night for five (5) more days. Please use the catheter provided by passing it *along the floor of the nasal passage* to 30cm from the tip of the catheter, inject 10ml of throat spray solution and then elevate his head to prevent it running out the nose. He tolerates this treatment well, but you may need to twitch him to assist passing the catheter. Please call if you need further instruction on administration
- Repeat endoscopy in 2 and 4 weeks' time. If fold swelling has resolved, training may then resume.
- Temperature should be taken twice daily for the first week. If there is any increase in temperature (above 38.5⁰ C), dullness of demeanour, loss of appetite or development of a cough or nasal discharge, please call.

Uncommon, though potential complications include intermittent dorsal displacement of the palate, slow resolution of the swelling and or re-entrapment. The prognosis for return to racing following treatment for this condition is considered very good.

Please call should you have any questions regarding this report.



.....N3860
Dr Jonathan Lumsden BVSc Dip VCS MS Dip ACVS
Specialist Equine Surgeon
RANDWICK EQUINE CENTRE